Cardiovascular System I: The Heart

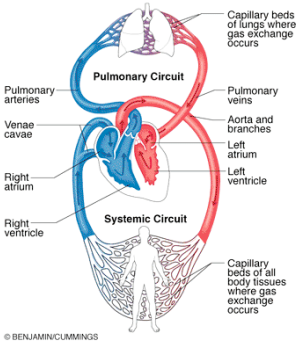

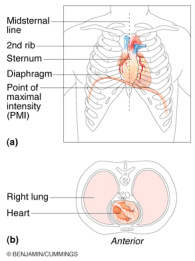

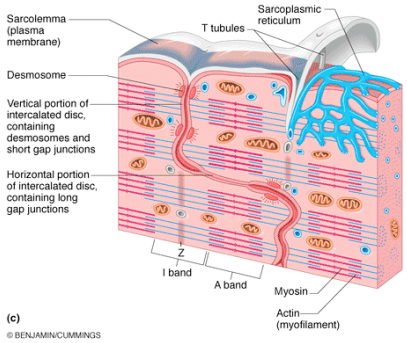

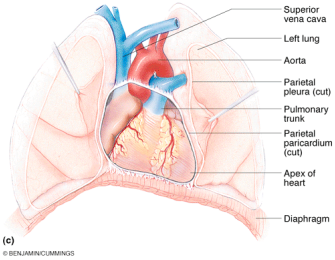

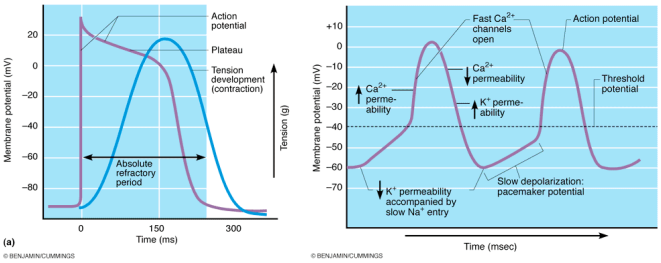

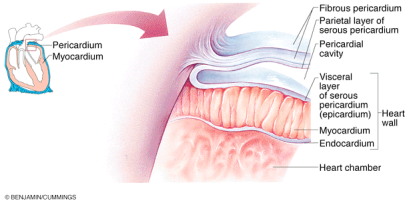

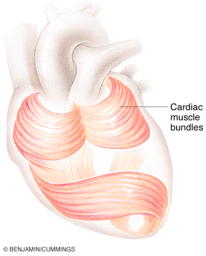

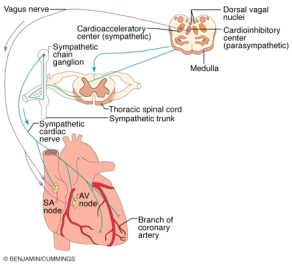

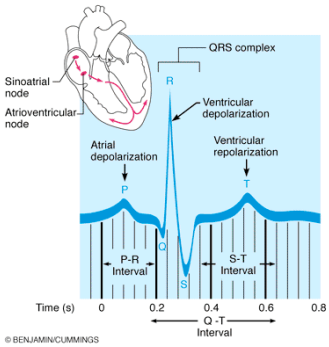

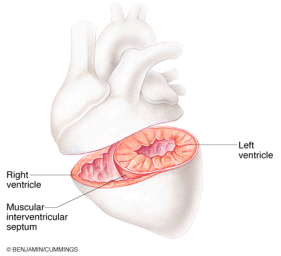

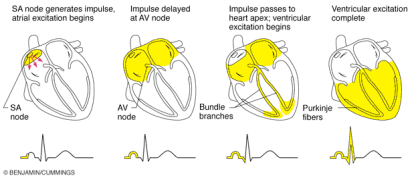

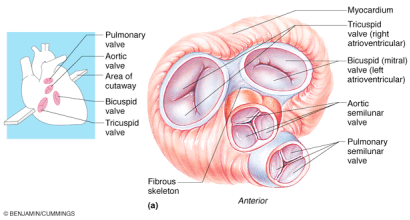

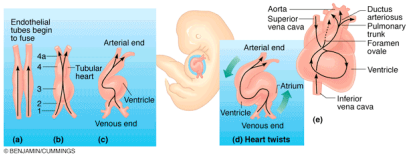

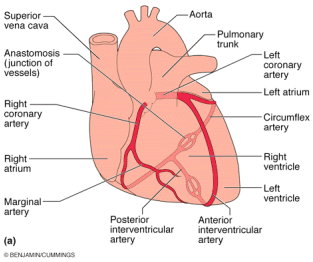

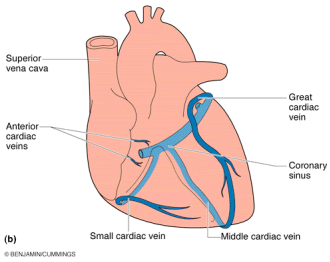

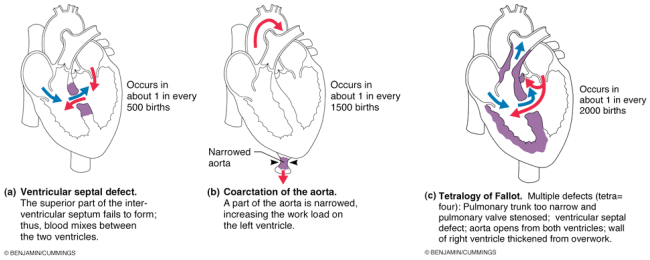

(a) Ventricular septal defect. The superior part of the interventricular septum fails to form; thus, blood mixes between the two ventricles.

(b) Coarctation of the aorta. A part of the aorta is narrowed, increasing the work load on the left ventricle.

(c) Tetralogy of Fallot. Multiple defects (tetra= four): Pulmonary trunk too narrow and pulmonary valve stenosed; ventricular septal defect; aorta opens from both ventricles; wall of right ventricle thickened from overwork.

© BENJAMIN/CUMMINGS