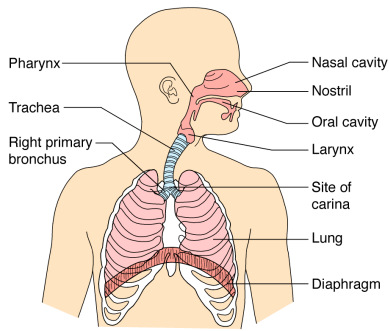
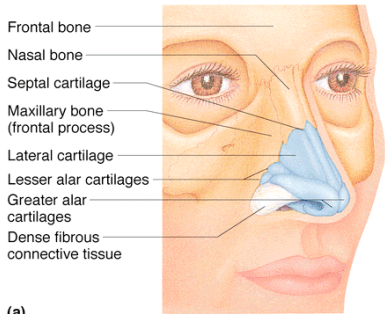


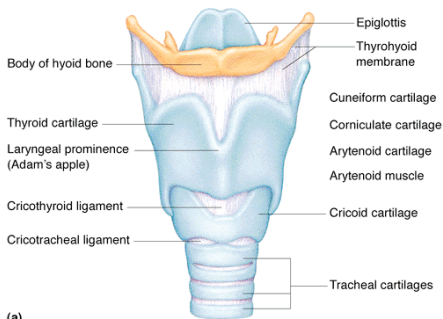
Respiratory Anatomy



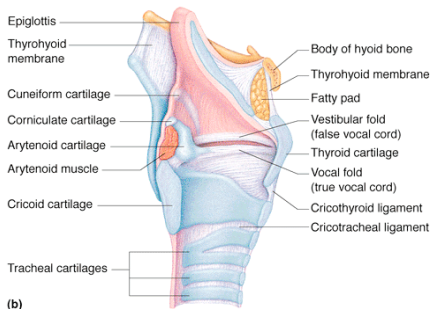
© BENJAMIN CUMMINGS



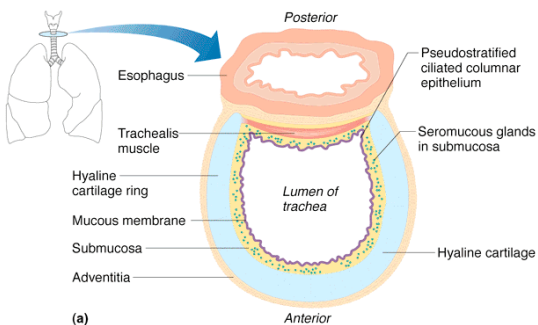
(a)
© BENJAMIN CUMMINGS



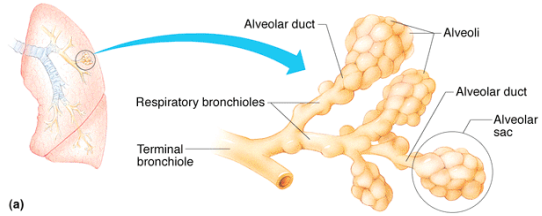
(a)
© BENJAMIN CUMMINGS



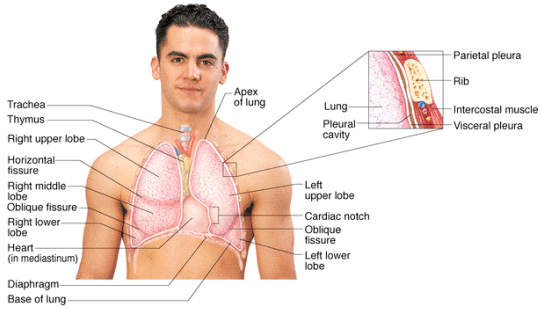
(b)
© BENJAMIN CUMMINGS



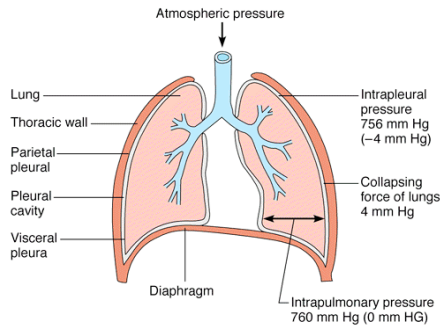
(a)
© BENJAMIN CUMMINGS



(a)
© BENJAMIN CUMMINGS



(a)
© BENJAMIN CUMMINGS



© BENJAMIN CUMMINGS

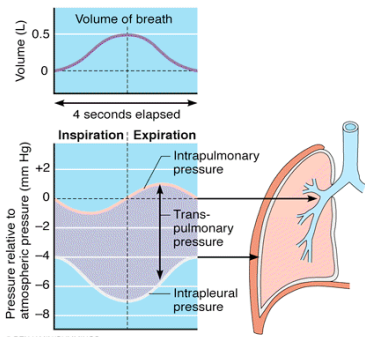
	Sequence of events	Changes in anterior-posterior and superior-inferior dimensions	Changes in lateral dimensions
Inspiration	<ol style="list-style-type: none"> Inspiratory muscles contract (diaphragm descends; rib cage rises) Thoracic cavity volume increases Lungs stretched; intrapulmonary volume increases Intrapulmonary pressure drops (to -1 mm Hg) Air (gases) flows into lungs down its pressure gradient until intrapulmonary pressure is 0 (equal to atmospheric pressure) 	Ribs elevated and sternum flares as external intercostals contract Diaphragm moves inferiorly during contraction	External intercostals contract

© BENJAMIN CUMMINGS

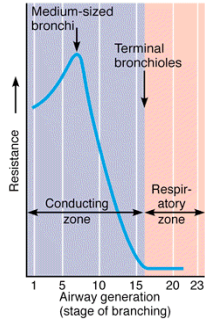
	Sequence of events	Changes in anterior-posterior and superior-inferior dimensions	Changes in lateral dimensions
Expiration	<ol style="list-style-type: none"> Inspiratory muscles relax (diaphragm rises; rib cage descends due to gravity) Thoracic cavity volume decreases Elastic lungs recoil passively; intrapulmonary volume decreases Intrapulmonary pressure rises (to +1 mm Hg) Air (gases) flows out of lungs down its pressure gradient until intrapulmonary pressure is 0 	Ribs and sternum depressed as external intercostals relax Diaphragm moves superiorly as it relaxes	External intercostals relax

© BENJAMIN CUMMINGS

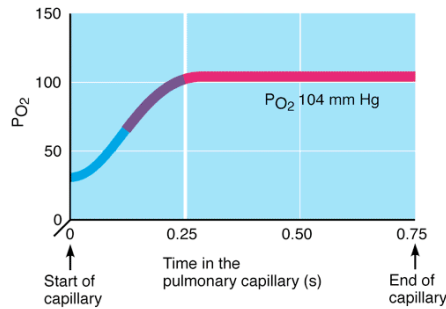
Respiratory Physiology



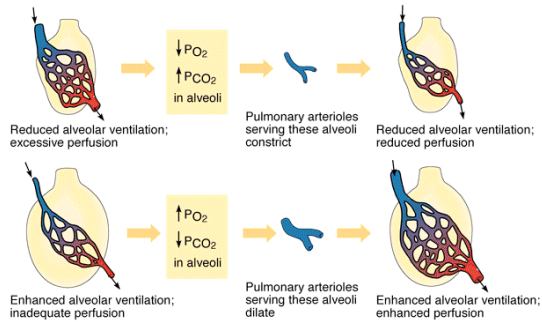
© BENJAMIN CUMMINGS



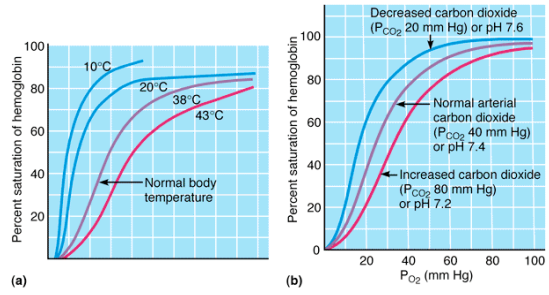
© BENJAMIN CUMMINGS



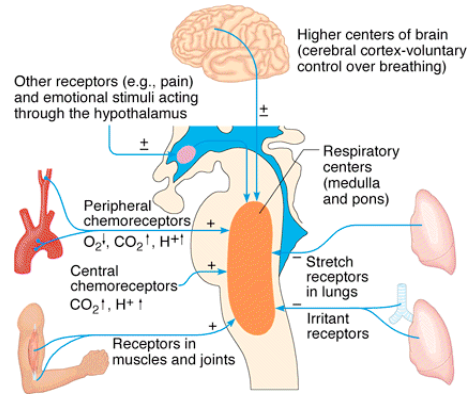
© BENJAMIN CUMMINGS



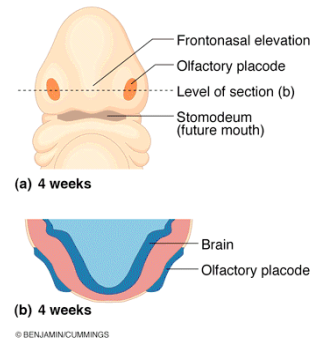
© BENJAMIN CUMMINGS



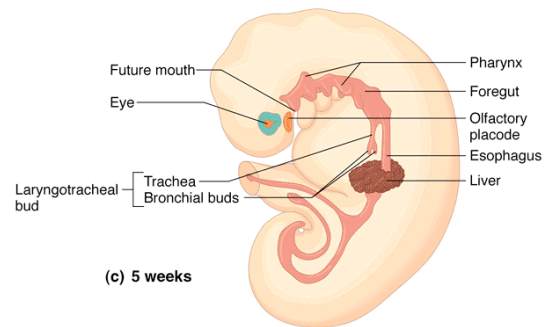
© BENJAMIN CUMMINGS



© BENJAMIN CUMMINGS



© BENJAMIN CUMMINGS



© BENJAMIN CUMMINGS